

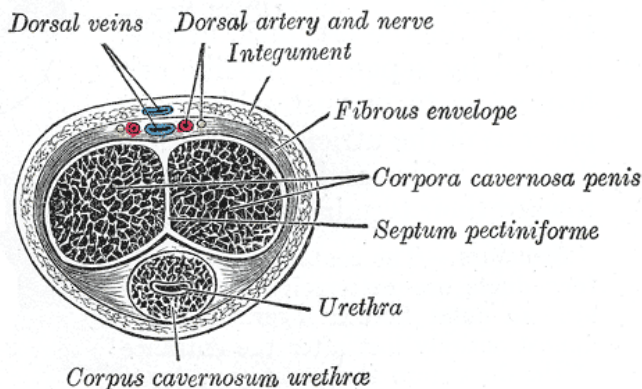
# Management of Priapism

Gabrielle Yankelevich, Mary Prickett, Tara Sweeney, Kyler Perry

## Introduction:

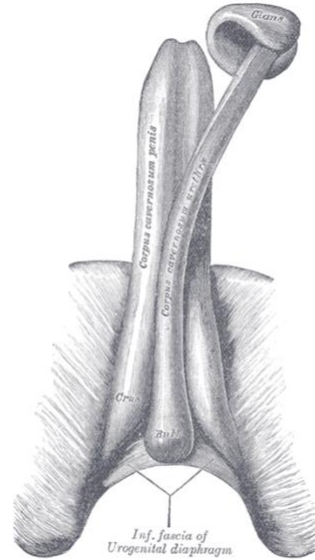
Priapism, an erection lasting longer than 4 hours, can be caused by trauma, neurologic conditions, medications, hematologic conditions (e.g. sickle cell disease), or idiopathic. The two types are ischemic (low-flow, occlusive) and non-ischemic (high-flow, non-occlusive). It is important to differentiate these presentations- non-ischemic priapisms are typically self-resolving, but ischemic priapisms are a **urologic emergency**. Longer ischemic times have higher rates of cavernosal fibrosis, which leads to permanent erectile dysfunction.

Knowing penile anatomy is important for both an anesthetic block and the priapism take-down procedure. The urethra is found on the ventral aspect of the penis, so this should be carefully avoided. The corpora are located dorsally and laterally. The dorsal veins, artery, and nerves are found on the dorsal midline of the penis.

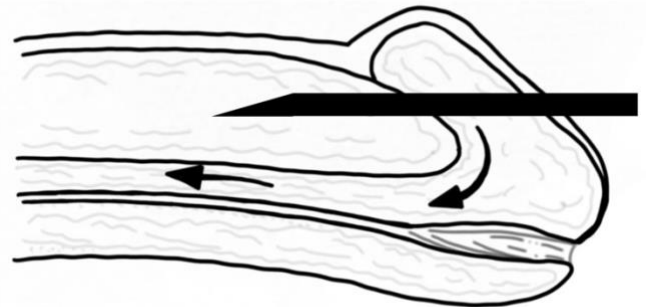


Cross-section of the penile shaft. The two erectile bodies are together called the corpora cavernosa (each erectile body individually is called a corpus cavernosum.) The corpora cavernosa is surrounded by the tunica albuginea, a thick fibrous sheath. The urethra is surrounded by a smaller structure that also fills with blood, the corpus spongiosum (here called corpus cavernosum urethrae). All shunts described here create a connection that allows each corpus cavernosum to drain into the corpus spongiosum.

The majority of priapisms can be resolved with corpus cavernosum aspiration and irrigation (+/- phenylephrine). Distal percutaneous or open shunts can be used if detumescence cannot be obtained with aspiration. Proximal shunts or venous anastomotic shunts are very rarely utilized due to success with distal shunts.



Corpora cavernosa, right and left, and their relation to the glans penis and corpus spongiosum (in this illustration called corpus cavernosum urethrae). Because of this relationship, creating an opening between the glans penis and the corpora cavernosa allows blood to drain out of the corpora into the glans and return to the body through the corpus spongiosum.



All distal shunts, either open or percutaneous, have in common the creation of an opening between the distal corpus cavernosum and the glans penis, as shown above, by piercing the tunica albuginea that lies between them. This allows blood to exit the corpus cavernosum through the glans into the corpus spongiosum, in the direction shown by the arrows.

It is important to consider whether a priapism is ischemic or non-ischemic, as the acuity and approach change between the two. Blood gas analysis, if available, can be helpful in determining which type of priapism is present. If you cannot measure blood gas, the clinical scenario can also guide you, as below:

## OPEN MANUAL OF SURGERY IN RESOURCE-LIMITED SETTINGS

[www.vumc.org/global-surgical-atlas](http://www.vumc.org/global-surgical-atlas)

This work is licensed under a [Creative Commons Attribution-ShareAlike 3.0 Unported License](https://creativecommons.org/licenses/by-sa/3.0/)



# Management of Priapism

Gabrielle Yankelevich, Mary Prickett, Tara Sweeney, Kyler Perry

## Non-Ischemic:

- Usually from trauma that causes arteriovenous fistula (can occur after ischemic priapism take-down also)
- Less rigid corpora, less or non-painful
- Ultrasound of corpora shows arterial flow
- Blood gas: normal pH, high pO<sub>2</sub>, low-normal pCO<sub>2</sub>  
pH: 7.4  
PO<sub>2</sub> > 90 mmHg  
PCO<sub>2</sub> < 40 mmHg
- Self-resolving: ice, ibuprofen, selective embolization or surgical fistula ligation if needed

## Ischemic:

- Sick cell disease, psychiatric or erectile medications, alpha-blockers, cocaine, etc.
- Very rigid and painful corpora
- Ultrasound of corpora shows no arterial flow
- Blood gas: acidosis, hypoxia, hypercarbia  
pH: < 7.25  
PO<sub>2</sub> < 30 mmHg  
PCO<sub>2</sub> > 60 mmHg
- Needs urgent decompression: corporal aspiration, shunting, open operation if needed

Management of ischemic priapism proceeds in the following steps:

- Dorsal and circumferential penis anesthetic block with lidocaine (without epinephrine)
- Place 16 or 18 gauge needle in 3 or 9 o'clock position, obtain sample, and irrigate corpora. Give phenylephrine if needed.
- If unable to take-down with aspiration, one or more shunting procedures should be utilized. Start with percutaneous (distal) procedures and escalate to open distal and then proximal procedures if unable to obtain detumescence.

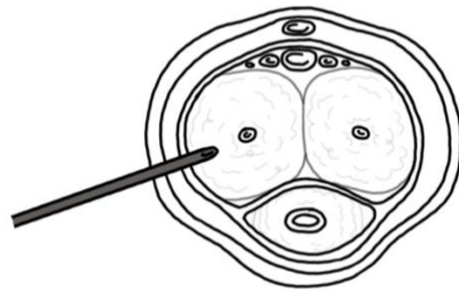
## **Steps:**

### Corporal Aspiration:

1. Place patient in supine position and on a cardiac/O<sub>2</sub> monitor. Pre-medicate the patient and have additional pain medications available if

needed. Prepare and drape the penis and scrotum. *Tip: place absorbent pads underneath the sterile drapes to catch blood and irrigant.*

2. Give a local dorsal and circumferential penile block with 1-2% lidocaine without epinephrine. Identify the pubic symphysis and angle the needle below the symphysis and slightly lateral bilaterally for the dorsal block. A circumferential (ring) block is given in a superficial fashion around the penis,
3. Place a 16- or 18-gauge needle into the 3 o'clock or 9 o'clock position. At a perpendicular angle, insert it directly into the corpus cavernosum and obtain a sample for blood gas analysis.



*Insert a needle into the corpus cavernosum at the three and nine o'clock positions, angling perpendicular or slightly towards the dorsum of the penis, to avoid injuring the corpus spongiosum and urethra.*

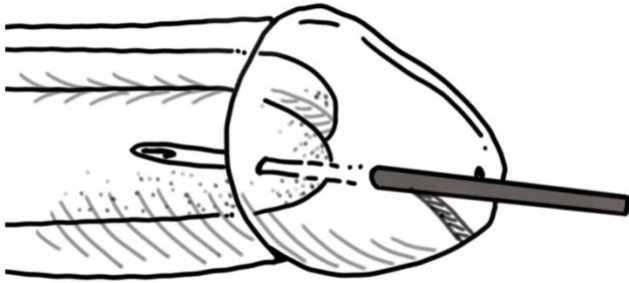
4. Aspirate blood using syringes and use sterile saline syringes to assist with irrigation.
5. Once the old blood has been evacuated, phenylephrine can be injected at a dose of 100-200 mcg every 3-5 minutes until detumescence (Epinephrine 1-2mL of 1:100,000 is acceptable: this can be diluted from vials of 1:1000 epinephrine for resuscitation.)

### Winter's Shunt (Corpoglanular):

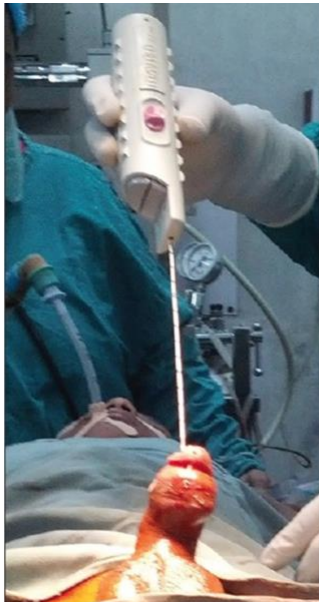1. Use an 18 gauge or larger biopsy needle and inject directly through the glans and into the corpus (parallel to the direction in which you would place a foley catheter but going on the dorsal aspect of the penis to avoid urethral injury).

# Management of Priapism

Gabrielle Yankelevich, Mary Prickett, Tara Sweeney, Kyler Perry

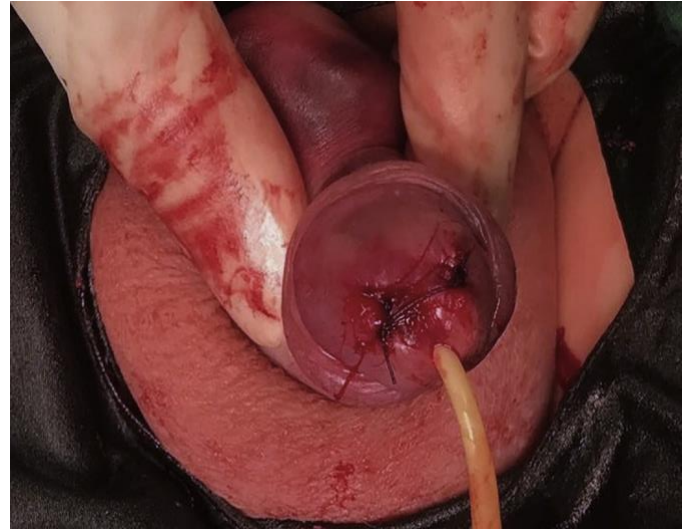

A large needle is inserted directly through the glans into the corpus cavernosum, on the dorsal and lateral side of the penis, parallel to the corpus spongiosum and urethra to avoid injury to this structure. This procedure is then repeated on the other side.



Using a core needle biopsy gun to create an opening between the glans and the corpus cavernosum, shown here on the patient's right side. Source: <https://doi.org/10.4103%2F0974-7796.165717>

2. Insert the needle several times to form multiple openings in the tunica albuginea. If needed, you can repeat on the other side, but this is not mandatory if detumescence occurs with one side.
3. If the skin continues to ooze, can close with a 3-0 chromic in a figure-of-eight fashion



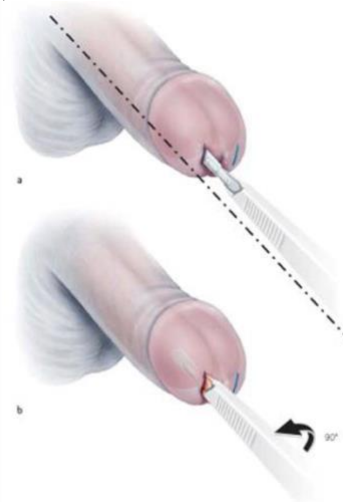
Appearance of the glans after bilateral distal corpoglanular shunt and closure of the skin with 3-0 chromic absorbable suture. Source: <https://doi.org/10.1016%2Fj.ajur.2019.12.010>

## Ebbehoj Shunt (Corpoglanular):

1. Same concept as Winter's shunt, but by using an 11-blade instead of a needle into the corpora
2. If the skin continues to ooze, close with a 3-0 chromic in a figure-of-eight fashion

## T-Shunt (Corpoglanular):

1. Same concept as Winter's and Ebbehoj shunt, but by using a 10-blade and first inserting parallel to the urethral meatus and then rotating 90 degrees away from the urethra (on the left corpora, rotate counterclockwise on the right corpora rotate clockwise)



The T-Shunt creates a larger connection between the glans and the corpus cavernosum by the insertion of a #10 scalpel blade



## Management of Priapism

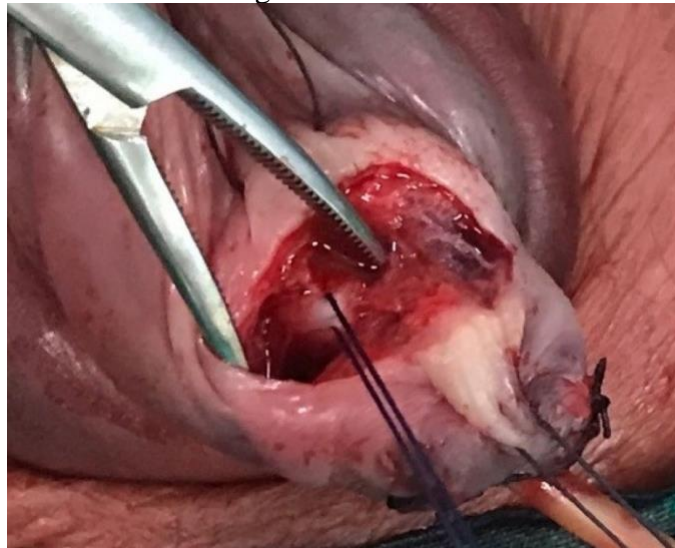
Gabrielle Yankelevich, Mary Prickett, Tara Sweeney, Kyler Perry

into the tissue between these structures. The blade faces dorsally and then is rotated laterally, away from the urethra. Source: <https://doi.org/10.1038%2Fnrrol.2009.50>

2. If the skin continues to ooze, close with a 3-0 chromic in a figure-of-eight fashion

### Al-Ghorab Shunt (Corporoglanular):

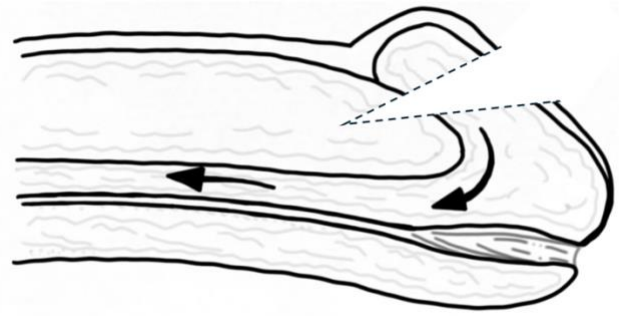
1. Same concept as above shunts but performed in the operating room with anesthesia. A tourniquet can be placed at the penile base to decrease bleeding. A foley can be placed to identify and avoid urethral injury.
2. Make a 1 cm transverse incision 1 cm distal to the coronal margin on the dorsal side.



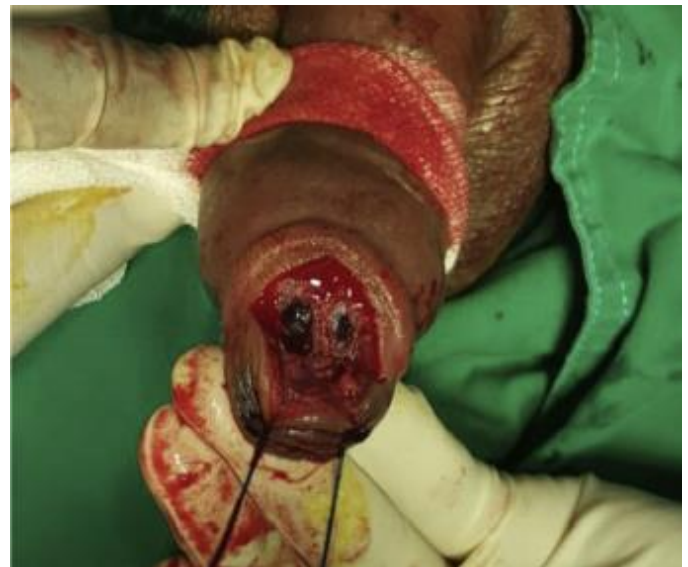After skin incision, dissecting through the glans reveals the white surface of the tunica albuginea covering the (right) corpus cavernosum. Source:

<https://doi.org/10.1016%2Fj.ajur.2019.12.010>

3. Expose the distal corpora and sharply excise a cone-shaped segment of tunica albuginea from both corporal bodies. Dark blood should be expressed and detumescence should occur once bright red blood is expressed. Do not close the corporal defect.



The Al-Ghorab shunt is created by excising a triangular wedge of tissue through the glans into both corpora cavernosa.



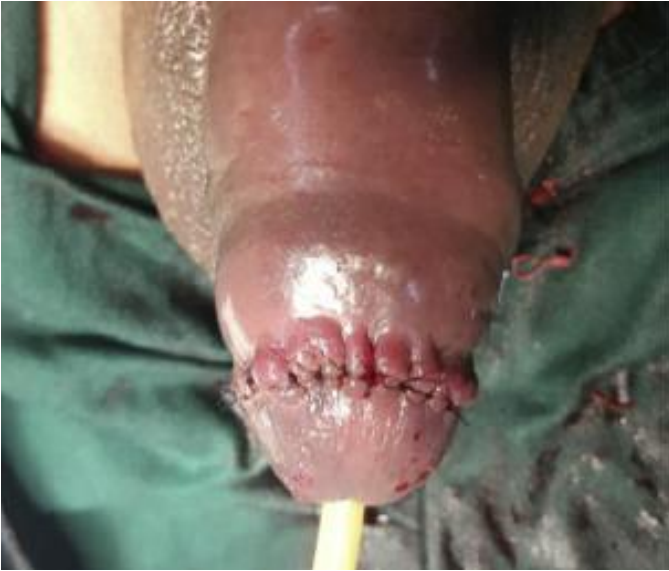The wedge excision through the glans passes into both corpora cavernosa, the black circles seen in the bottom of this wound.

Source: <https://doi.org/10.1016%2Fj.eucr.2017.01.011>

4. Close the skin with 3-0 chromic

## Management of Priapism

Gabrielle Yankelevich, Mary Prickett, Tara Sweeney, Kyler Perry



Appearance of the glans following skin closure after the Al-Ghorab shunt. Source:

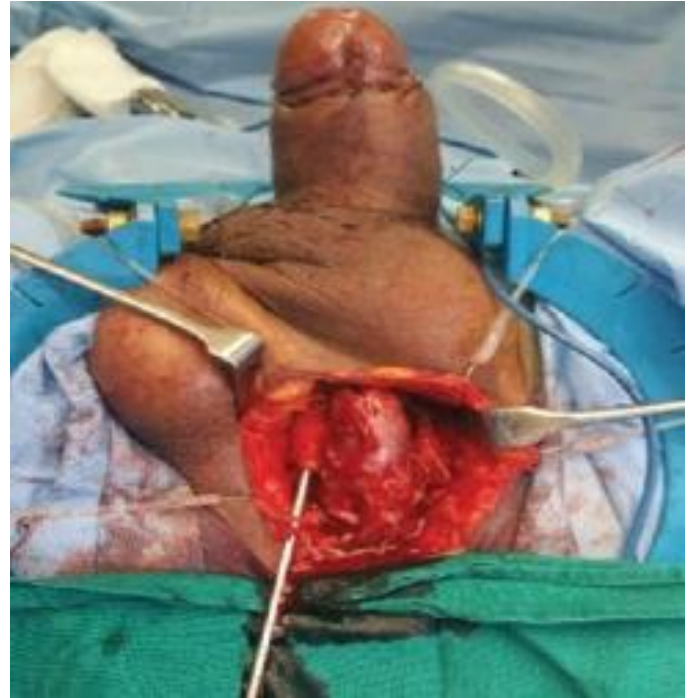<https://doi.org/10.1016%2Fj.eucr.2017.01.011>

### Open Burnett (Distal Corporoglanular Shunt):

1. Starts with the same exposure as the Al-Ghorab shunt, but after excision in the tunica, place a 7-8 mm Hegar dilator and insert into the proximal corpora at a slight lateral angle to avoid the urethra. Dark blood should be expressed and detumescence should occur once bright red blood is expressed. Do not close the corporal defect.
2. Close the skin with 3-0 chromic

### Open Quackels (Proximal Corporospongiosal Shunt):

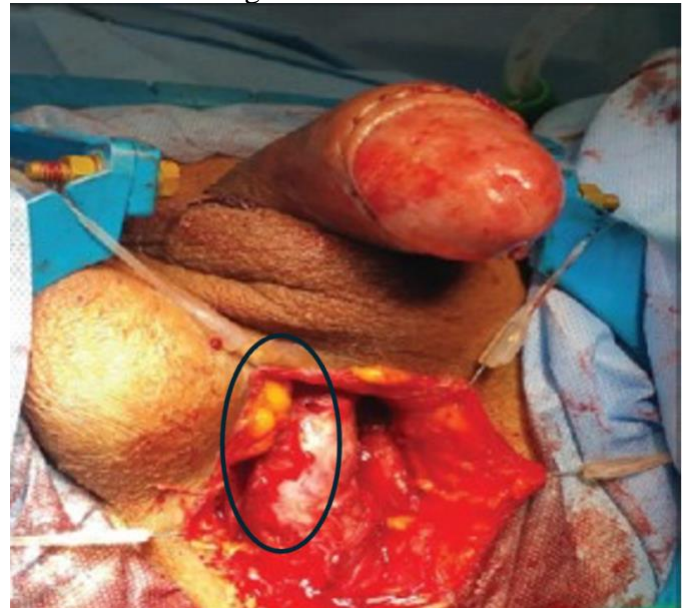1. In the operating room under anesthesia, place patient in dorsal lithotomy, place a foley catheter, and make a 5 cm vertical perineal incision in the midline.
2. Carry the incision to the level of the bulbocavernosus muscle and incise or excise a 1 cm vertical portion of corpus spongiosum, take extreme care to not injure the urethra which runs in the center of this structure.
3. Make a parallel incision into one adjacent corporal body and irrigate the blood. If detumescence is not achieved, perform bilaterally.



Incision into the right corpus cavernosum adjacent to the corpus spongiosum. In this photo, a metallic sound is being used to evacuate clotted blood from the corpus cavernosum.

Source: <https://doi.org/10.4103%2FUA.140.18>

4. After detumescence, use a running 5-0 PDS suture to re-approximate the spongiosum and cavernosum together



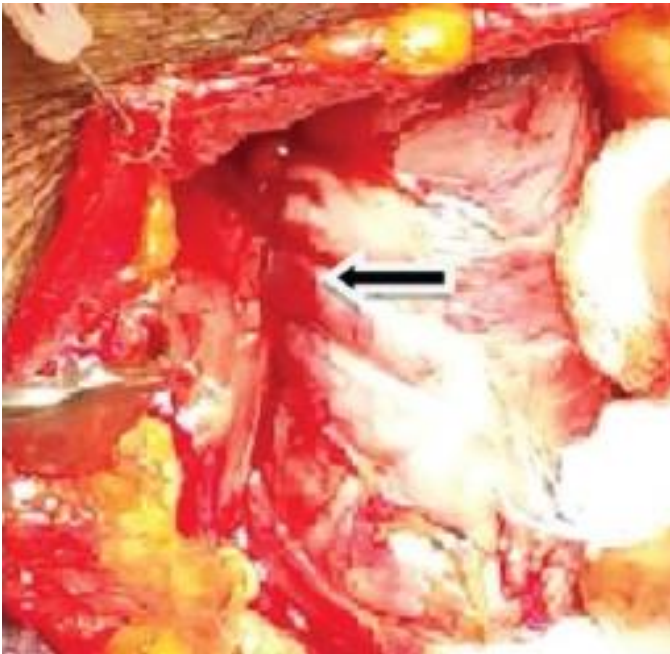After adjacent incisions in the corpus cavernosum and the corpus spongiosum (shown here on the patient's Left side) the two structures are sewn together. Source:

<https://doi.org/10.4103%2FUA.140.18>



## Management of Priapism

Gabrielle Yankelevich, Mary Prickett, Tara Sweeney, Kyler Perry



Close-up detail of the anastomosis between the right corpus cavernosum and the corpus spongiosum. Source:

[https://doi.org/10.4103%2FUA.UA\\_140\\_18](https://doi.org/10.4103%2FUA.UA_140_18)

convert to a non-ischemic (high-flow) priapism, which can be confirmed with blood gas or color duplex ultrasonography showing arterial flow. These can be managed conservatively with ice and pain medications.

- Utilize a cardiac monitor because phenylephrine can cause hypertension, bradycardia or tachycardia, cardiac arrhythmias, and headaches. Maximal dose of phenylephrine is 1000 mcg/hour.
- Consider antibiotics to cover skin flora for 1 week, as the consequences of an infection in the corpus cavernosum can be devastating.

Gabrielle Yankelevich, DO

Mary Prickett BS

Tara Sweeney, MD

Kyler Perry, DO

Medical University Of South Carolina

USA

*All illustrations by Mary Prickett except Gray's Anatomy images or as otherwise noted.*

July 2024

5. Re-approximate the bulbocavernosus muscle with 3-0 absorbable suture, dartos fascia with 2-0 absorbable suture, and close the skin with 3-0 chromic.

### Pitfalls

- After any aspiration or shunting procedure, gently wrap the penis with gauze for a lightly compressive dressing. Avoid an overly tight dressing as this could worsen the ischemic process.
- Patients may fail a voiding trial due to penile edema, so a catheter can be replaced and trial of voiding repeated once edema has decreased.
- For priapism lasting longer than 72 hours, patients have almost a 100% chance of erectile dysfunction, so these patients should go to the operating room for surgical decompression and ideally placement of a penile prosthesis. Delay in placement of a prosthesis leads to difficulty in placement later, with increased rates of scarring, erosion, infection, and even urethral injury.
- After take-down of an ischemic priapism, especially with shunting procedures, patients can

**OPEN MANUAL OF SURGERY IN RESOURCE-LIMITED SETTINGS**

[www.vumc.org/global-surgical-atlas](http://www.vumc.org/global-surgical-atlas)

This work is licensed under a [Creative Commons Attribution-ShareAlike 3.0 Unported License](https://creativecommons.org/licenses/by-sa/3.0/)

