

Recognizing Postoperative Intra-Abdominal Sepsis

Richard Davis, Winnie Mutunga

Background:

Postoperative intra-abdominal complications can be challenging to diagnose and treat for even the experienced surgeon. Many of the signs and symptoms that can signal infection in the abdomen, such as pain, tachycardia, and fever, will already be present or can be “blamed on” the postoperative state. The examination is also compromised; extreme tenderness and even peritoneal irritation are always present after surgery. And other, non-surgical conditions such as pulmonary embolism, pneumonia, wound infection, and urinary tract infection can cause signs and symptoms that are similar to intra-abdominal infection.

In this chapter we present our overall approach to patients after laparotomy. The surgeon must be very vigilant during the first 5-10 days after laparotomy, especially if a bowel anastomosis was done. During this time period, to borrow a quote from the author Chinua Achebe, “things fall apart.”

Anatomy and Physiology:

The Inflammatory Reaction:

After surgery, the patient will undergo an inflammatory reaction. The greater the insult, the greater the reaction. This reaction is associated with surges of catecholamines, glucagon, and cortisol, the body’s stress reaction. Although we do not usually measure these substances, we can follow the inflammatory reaction. It is signaled by:

- Tachycardia
- Hypotension
- Tachypnea
- Low oxygen saturation
- Low urine output
- Peripheral edema
- Ileus

The most important concept in this chapter is the following one: **It may be normal to have all of these signs for a certain period after the surgery, but they should not persist.** The amount of time that these signs will “normally” be present varies depending on the magnitude of the surgical or traumatic insult. The surgeon must therefore watch all of these signs very carefully during the patient’s convalescence. This is because, **after an uncomplicated surgery, the inflammatory reaction will be self-limited. When complications**

set in, signs of inflammation will either reappear, or fail to resolve.

While we focus here on intra-abdominal complications, keep in mind that most forms of surgical illness will follow this course. Complications become apparent when the inflammatory reaction fails to resolve- this occurs with soft tissue infections, ischemia, and abscesses.

Healing of Intestinal Anastomoses:

When bowel edges are sutured together, the tissue follows a predictable course of healing. The surgeon must have an understanding of this process, especially regarding ways in which it can go wrong. There are two “windows” of time after creation of an anastomosis, when it is prone to leakage.

In the presence of adequate blood supply, the bowel tissue becomes weakest between days 3-5. This is the **inflammatory** phase of wound healing and the main activity in the wound is lysis of collagen. During this time, macrophages and neutrophils invade the wound and remove dead tissue. Technical errors will manifest themselves during this time. These include failing to suture adequate tissue, including devitalized tissue in the anastomosis, or making the lumen of the anastomosis too small. Assuring that the serosa is approximated (when present) is an excellent way to assure that the anastomosis is “waterproof” and will last through this phase. This is why anastomoses to the rectum or esophagus, without serosa, are more prone to leakage.

Another technical error is failing to incorporate all of the bowel in the anastomosis, in effect leaving a hole in the bowel. The best way to avoid this mistake is to pay strict attention to technical details while creating the anastomosis. This type of error will manifest itself around day 3-5 as well; enteric contents will start passing through the anastomosis at this time as ileus temporarily resolves. (Ileus will return, however, in the presence of leakage.) Therefore, days 3-5 constitute the first “window” for anastomotic leakage.

The second “window” occurs around day 7-12. An anastomosis that is performed technically well will be in the **proliferative** stage at this time. Problems occur if blood supply is inadequate for this stage; collagen deposition will be inadequate and the

Recognizing Postoperative Intra-Abdominal Sepsis

Richard Davis, Winnie Mutunga

healing process will stop, resulting in leakage. These “late leaks” are more rare, but they occur when anastomosis is done on bowel that is not adequately perfused. These patients may have return of bowel function before this happens. They might even be discharged from the hospital.

The classic scenario where poor blood supply can lead to a late leak is a left colon resection and anastomosis in the left transverse colon, in the “watershed” area between the superior and inferior mesenteric arteries. In this area we usually resect further, preferring to remove more bowel until the anastomosis can be made using colon that is adjacent to two pulsatile vessels.

For more details, see the Chapter on Intestinal Anastomosis.

Principles:

In large surgeries, the inflammatory reaction will involve the whole body, but should follow a self-limited course. The careful surgeon will watch for signs that it is decreasing. The experienced careful surgeon, having cared for many patients after surgery, will know how long inflammation should last, based on the magnitude of the surgery.

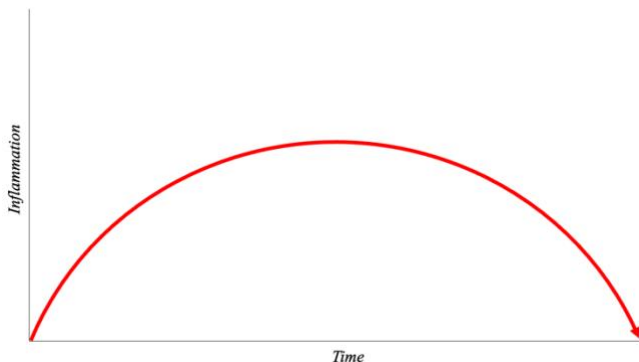


Diagram showing the normal pattern of inflammation after a large surgery. Of note, the amount of the inflammation (height of the curve) and the time at which it peaks will depend on the magnitude of the operation. An experienced surgeon will understand how this curve “should” look for a given operation, and when a patient is deviating from it.

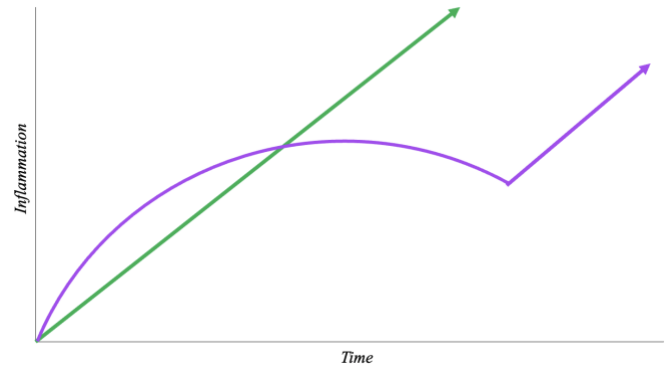


Diagram showing inflammation when there is unrecognized pathology, such as an intra-abdominal abscess or anastomotic leakage. In the patient represented by the Green arrow, the complication began before the inflammation could resolve. The patient represented by the Purple arrow developed a late complication, deviating from what would have otherwise been a normal postoperative course.

The heart rate is the main and earliest signal of things falling apart. If the patient has been adequately resuscitated, tachycardia has usually resolved by the first postoperative day. Exceptions include patients who had sepsis before surgery (such as perforated duodenal ulcer) or patients who had a massive traumatic insult. But after a large elective surgery such as gastrectomy or colectomy, tachycardia should not be present on the first postoperative day. If it is, determine whether the patient’s pain is adequately controlled. If pain is controlled, give a fluid bolus and monitor the heart rate response. Check the hemoglobin level as the patient may be anemic. It is unlikely that anastomotic leak will manifest on the first day after surgery.

Tachycardia which appears after the 3rd or 4th day in a patient who was previously well is more worrisome. Carefully assess the patient’s other parameters: measure their radial pulse yourself and assess the respiratory rate. If both are elevated, or if there is fever, this warrants further investigation. The first step is to talk to the patient. Have they passed flatus yet? Are they having difficulty urinating? Have they ambulated? Do they have a cough or shortness of breath? Then, do a thorough physical exam checking for crackles in the lungs or any tenderness anywhere, including the calves. Examine the wound for induration or erythema: sometimes the problem is a wound infection. Do not hesitate to open part of the wound if you suspect this.

Recognizing Postoperative Intra-Abdominal Sepsis

Richard Davis, Winnie Mutunga

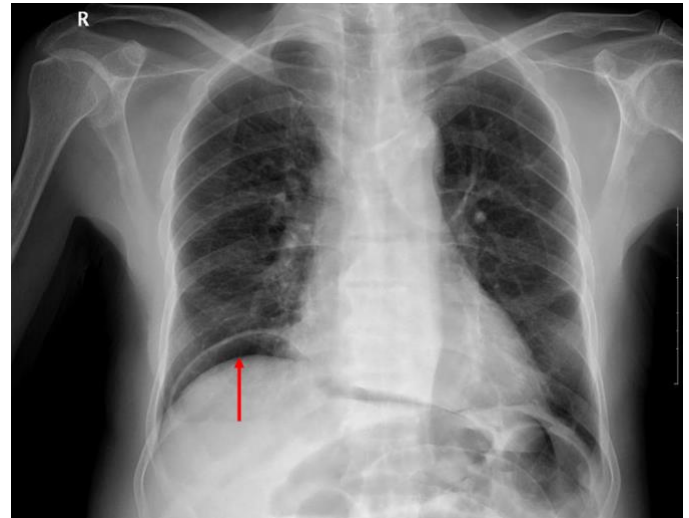
If foul-smelling fluid comes out of the wound when opened, it may be a simple wound infection, or something worse. If bilious or feculent fluid come out, or if purulent fluid continues to drain, or if you feel a defect in the fascia in a patient with purulent wound discharge, return to the operating room for a careful exploration. See “[Closure of Laparotomy Wound Dehiscence](#).”

Unfortunately, in a postoperative patient the abdominal examination will not be very helpful. Nevertheless, palpate all of the abdomen gently, understanding that it will be painful to the patient. If the patient is cooperative, you can repeat this examination later to assess their progress; be reassured if there is some improvement.

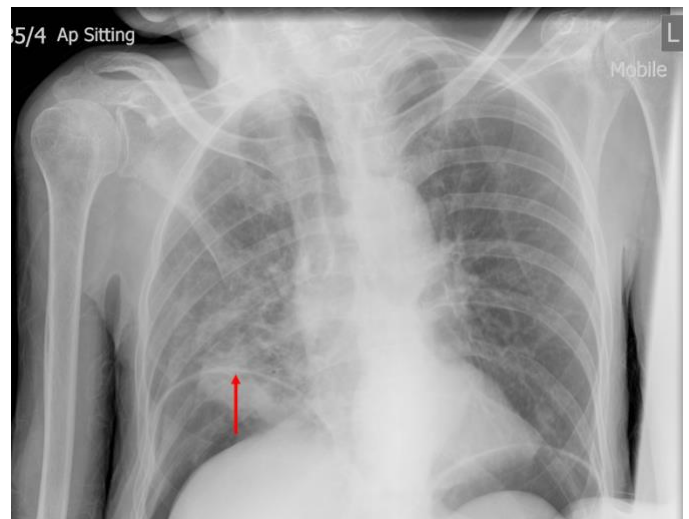
Resolution of ileus is a very reassuring sign that things are going well inside the abdomen. The colon and rectum recover from ileus last, so if the patient has flatus you can be sure that the stomach and small bowel are active. An exception to this rule is diarrhea: if the patient has diarrhea you have not ruled out anastomotic leakage or intra-abdominal abscess. Remember that if you give a patient water-soluble oral contrast, they will often have diarrhea on the following day- this is normal.

Plain abdominal or chest x-rays can be very useful. If the patient can stand or sit upright, have them do so for 3-5 minutes before taking a chest x-ray, to allow any intraperitoneal air to rise into the subdiaphragmatic space. If the patient cannot stand, have them lie with their left side down for 3-5 minutes before taking a lateral decubitus x-ray in that position (not supine!) The lateral decubitus x-ray takes advantage of the lack of bowel gas in the area of the liver- any gas seen in the left upper quadrant is likely outside the bowel.

In general, the free air from an operation will resolve after 24 hours, 48 maximum. If you see free air in the abdomen after postoperative day 2, don't fool yourself that it is left over from your operation: your patient's anastomosis is leaking.



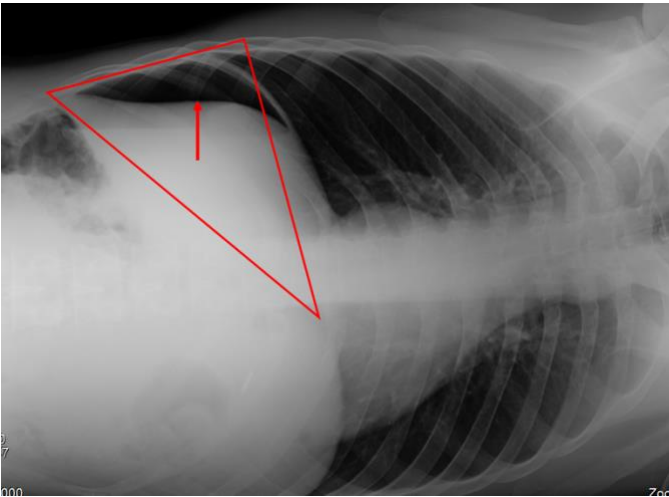
Air under the right hemidiaphragm (Red arrow) in an upright chest x-ray. Sometimes the air may be a very small amount, but any air in this position is abnormal (unless it is clearly part of the transverse colon, which can rarely migrate above the liver.) Case courtesy of Dr Varun Babu, from the case <https://radiopaedia.org/cases/19474?lang=us>



Sometimes the pneumoperitoneum is so large that the diaphragm can be confused for a lung marking, as shown by the Red arrow. One clue that this is the case is the unnatural appearance of the “false right hemidiaphragm,” which is actually the liver. Note also the clearly seen air under the left hemidiaphragm. Case courtesy of Dr Jeremy Jones, from the case <https://radiopaedia.org/cases/6129?lang=us>

Recognizing Postoperative Intra-Abdominal Sepsis

Richard Davis, Winnie Mutunga



The anteroposterior abdominal x-ray taken in the left lateral decubitus position takes advantage of the liver, which displaces any bowel. The area within the Red triangle is usually gasless on abdominal x-ray. In this case, a large collection of free intraperitoneal air is seen within this space, shown by the Red arrow. Case courtesy of Dr Prashant Mudgal, from the case <https://radiopaedia.org/cases/33973?lang=us>

Decision Making:

There are many things that could give your patient tachycardia or fever after surgery: pneumonia, urinary tract infection, pulmonary embolus, wound infection, and others. Although you would not want to miss any of these diagnoses, you should always take the following attitude: **Increasing inflammatory markers in a patient after abdominal surgery is intra-abdominal sepsis until proven otherwise!**

A classic pitfall is blaming the patient's deviation from "normal" on some other condition. You may feel tenderness in the calf and confirm a deep venous thrombosis by doppler ultrasound, leading you to believe that the tachycardia and hypoxia are due to pulmonary embolism. You may check a chest x-ray and see an infiltrate, leading you to believe that tachycardia and hypoxia are due to pneumonia. And yes, postoperative patients do get these problems. But they could just as easily be manifestations of a more serious intra-abdominal problem. The systemic inflammation caused by intra-abdominal sepsis leads to disordered coagulation and venous thrombosis. The abdominal pain from peritonitis leads to poor pulmonary hygiene and pneumonia.

This is not to say that every postoperative complication is automatically caused by intra-

abdominal sepsis. Rather, we want you to be vigilant. After any operation that leaves a suture line in the abdomen, anastomotic leakage should always be at or near the top of your list of suspects.

When a postoperative patient has new onset tachycardia, fever, elevated respiratory rate, or elevated oxygen requirement, check a white blood cell count and differential. An elevated WBC with a "left shift" (increased neutrophil percentage) is diagnostic for untreated infection, unless the values are decreased compared to the admission values. At this point you may either do imaging, if this is available to you, or explore the abdomen if no other diagnosis is apparent.

Overall, we are looking for early signs of inflammation, so we can intervene before the inflammation becomes life-threatening. Bear in mind that these signs we watch for are even more subtle in patients who can not mount an immune response. Such patients include the elderly, the immunosuppressed, and those who will not become tachycardic because of beta blockade or heart block. Conversely, patients on systemic steroids will have an elevated white blood cell count and left shift, which may not reflect infection.

To make the diagnosis, if possible obtain an x-ray study that shows enteric contrast passing through the anastomosis. This is possible with anastomoses in the rectum, rectosigmoid junction, esophagus, stomach and duodenum. Use water-soluble contrast such as gastrografin (meglumine-diatrizoate.) Barium will cause mediastinitis or peritonitis if it comes in contact with these surfaces. If you have fluoroscopy, these studies can be done under your supervision and you can make sure you are satisfied with the quality of the images. Otherwise, instruct the x-ray staff on what part of the gastrointestinal tract you are hoping to see, and they will time their images accordingly.

If you have a CT scan available, these images will be more useful than plain x-rays. If you can give IV contrast, you can distinguish abscesses from non-infected fluid collections by the presence of rim enhancement in an abscess. But you do not need to give IV contrast, as the most important thing you are looking for is active leakage of enteric contrast, or any of it outside the bowel.

Recognizing Postoperative Intra-Abdominal Sepsis

Richard Davis, Winnie Mutunga

Case Studies:

Case #1: JA, 60 year old otherwise healthy woman underwent an [Antrectomy and Bilroth 1 Reconstruction](#) for obstructive peptic ulcer disease. Surgery was uneventful. She has not had flatus postoperatively but has been afebrile, with heart rate consistently <90 beats per minute. The surgical team which performed her operation has seen her every day.

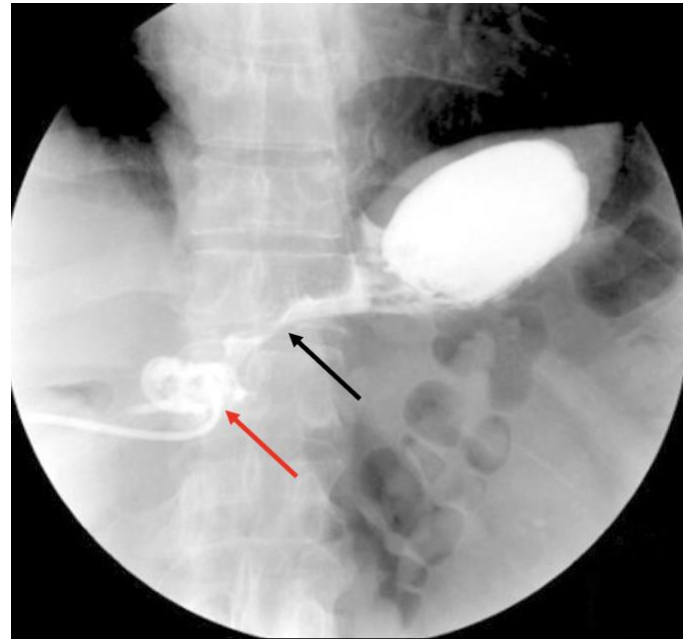
On postoperative day 5, her heart rate is noted to be 115 beats per minute. Her blood pressure is 110/80. She is not nauseated but has not yet passed flatus. Her urine output has not been recorded, as her foley catheter was removed several days ago.

On examination, her abdomen is nondistended. There is mild generalized tenderness. Her wound is clean and dry without erythema or discharge, and her abdominal drain output is minimal, clear yellow non-bubbly fluid. Her sclerae are noted to be normal in color and not pale. Lung auscultation does not reveal crackles or diminished lung sounds. She is given a bolus of 500mL of Ringer's Lactate. At this time, the following differential diagnoses are considered:

- Intra-abdominal abscess
- Anastomotic leakage

The team orders a complete blood count and a gastrografen (water soluble contrast) swallow study. They discuss with the radiography team and ask them to obtain images immediately after administering 50mL of gastrografen, as the area of interest is the stomach.

The images clearly show leakage of contrast, emptying into a small area that is evacuated by the drain:



Swallow study with water-soluble contrast shows the site of leakage from the anastomosis (Black arrow) and the collection of contrast adjacent to the tip of the drain, with contrast within the drain (Red arrow.) Source: Dong Woo Hyun, Ki Hyun Kim et al, <https://doi.org/10.7602/jmis.2018.21.1.13>

The complete blood count returns the following results:

White blood cells: 22.26

Neutrophils: 92%

Hemoglobin 8.8g/dL

Platelets 667

At this time the patient is explained the complication and she agrees to return to the operating room. Excessive tension on the gastroduodenostomy is found, with an anastomotic dehiscence of about 20% of the circumference. The entire anastomosis is taken down and converted to a Roux-en-Y reconstruction, and a feeding jejunostomy is placed distally. The abdomen is washed out. Postoperatively, she is started on IV antibiotics.

Comment: This team acted well, seeing the patient daily and recognizing an early sign of intra-abdominal sepsis. Note also that they did not add "Pneumonia" or "Urinary Tract Infection" to their differential diagnosis- they correctly assumed that the cause of sepsis was the site of their operation. They did not start the patient on antibiotics and hope she would improve, a move that would have only delayed recognition and treatment of this problem.

Recognizing Postoperative Intra-Abdominal Sepsis

Richard Davis, Winnie Mutunga

Some learning points from this case:

- *The earliest sign of infection after intra-abdominal surgery will be tachycardia. An elevated WBC with tachycardia must be taken seriously.*
- *The diagnosis is an intra-abdominal process that needs intervention until proven otherwise. Do not assume it's pneumonia.*
- *If you do not have a CT scanner, it is better to re-operate early when you suspect sepsis. If you wait to intervene, surgery will be much more dangerous for the patient, as the inflammatory cycle will have been ongoing. In this patient, all other signs pointed to an intra-abdominal process. If the x-ray swallow study did not show an anastomotic leak, it would have been reasonable to re-explore the patient anyway.*
- *The lack of purulent discharge from the drain does not rule out anastomotic leakage.*

Case #2: BD, a 70 year old man with a past history of asthma and bronchitis, undergoes elective left hemicolectomy for non-obstructing colon cancer. A stapled anastomosis is performed. His morning and afternoon vital signs are as follows:

| Postop. Day | Heart Rate | Resp. Rate | Temp(C) |
|-------------|------------|------------|---------|
| 3 (6AM) | 81 | 19-24 | 37 |
| 3 (4PM) | 87 | 22-24 | 37 |
| 4 (6AM) | 112 | 21-24 | 38.1 |

On the morning of Postoperative Day 4, as above, the patient's heart rate is noted to be 112 and temperature elevated to 38.1. The blood pressure is within normal limits. He is not nauseated and has not yet passed flatus. Urine output is unknown, as the foley catheter was removed the previous day.

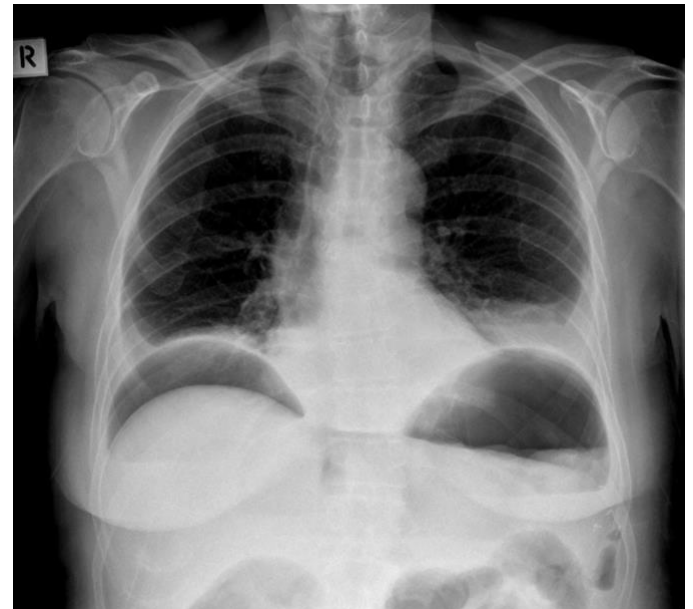On examination, his abdomen is nondistended. There is mild generalized tenderness. The wound is clean and dry without erythema or discharge. His sclerae are noted to be normal in color and not pale. Lung auscultation reveals decreased

breath sounds on the left side. A plain chest x-ray shows no sub-diaphragmatic air and a small consolidation of the left lower lobe. A diagnosis of pneumonia is made and the patient is started on piperacillin-tazobactam.

Morning and afternoon vital signs continue as follows:

| Postop. Day (Time) | Heart Rate | Resp. Rate | Temp(C) |
|--------------------|------------|------------|---------|
| 4 (4PM) | 89 | 18-22 | 37.4 |
| 5 (6AM) | 110 | 17-27 | 37.7 |
| 5 (4PM) | 115 | 18-26 | 37.4 |
| 6 (6AM) | 118 | 22-30 | 38 |

On Postoperative Day 6 as above, the patient is clearly unwell with tachypnea and hypotension. His abdomen is distended and peritonitic. He has not yet passed flatus. The team obtains a chest x-ray, which shows:

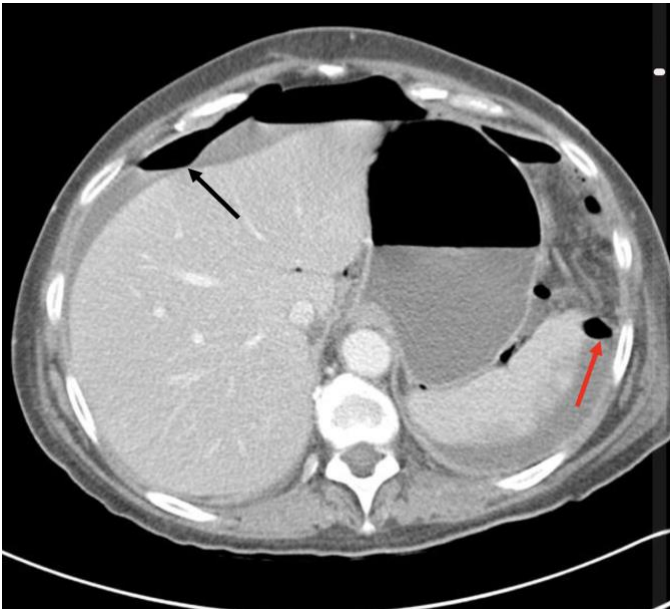


Plain upright chest x-ray shows free air under both the right and left hemidiaphragm. Case courtesy of Knipe, H, from the case <https://radiopaedia.org/cases/25402>

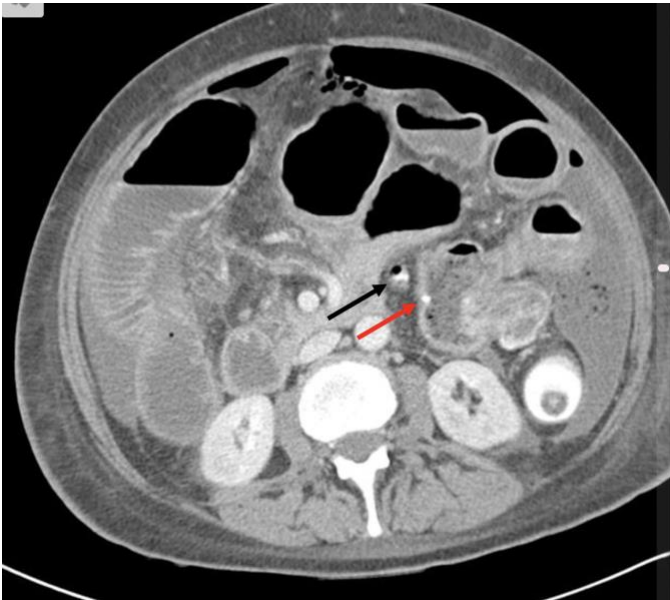
A diagnosis of anastomotic leakage is considered. The team obtains a CT scan with intravenous and rectal water-soluble contrast, which shows:

Recognizing Postoperative Intra-Abdominal Sepsis

Richard Davis, Winnie Mutunga



CT scan of the upper abdomen shows free air and fluid anterior to the liver (Black arrow) and posterior to the spleen (Red arrow.) Case courtesy of Knipe, H, from the case <https://radiopaedia.org/cases/25402>



CT scan of the lower abdomen shows a small amount of contrast extravasation (Black arrow) adjacent to the anastomosis, whose location can be clearly seen because of the staples (Red arrow.) Case courtesy of Knipe, H, from the case <https://radiopaedia.org/cases/25402>

The patient is taken for laparotomy and washout. He is noted to be hypotensive and tachycardic throughout the operation. The anastomosis is taken down and a Hartmann colostomy is fashioned. He requires ventilator support for 1 week after surgery and his

hospitalization lasts 5 weeks in total. He eventually recovers. His hospital bill is far in excess of what his family is able to pay at the time of discharge.

Comment: *It is quite clear from a review of the vital signs that this patient's anastomotic leak began on the night between Postoperative Day 3 and 4. The signs were there for the team to recognize but instead they made a diagnosis of "Pneumonia." Once this was done, they were perhaps reassured by a transient decrease in heart rate on the afternoon of Postoperative Day 4. The overall effect of this misdiagnosis was a delay of 48h. During this time, the anastomosis continued to leak and the sepsis got worse.*

If the team had chosen to investigate on Postoperative Day 4 with a water-soluble contrast enema x-ray series, or a CT scan with rectal contrast, it is possible that they could have repaired the anastomotic leak with an omental patch or otherwise avoided a colostomy. Also, if they had operated on Day 4 instead of 6, it is certain that the patient would have been more fit for operation, and would not have needed prolonged intubation afterwards.

Some learning points from this case:

- *The earliest sign of infection after intra-abdominal surgery will be tachycardia. A fever with tachycardia must be taken seriously.*
- *The diagnosis is an intra-abdominal process that needs intervention until proven otherwise. Do not assume it's pneumonia.*
- *A plain chest or abdominal x-ray that shows free intra-abdominal air >48 hours after surgery is all the proof you need of anastomotic leakage. No other imaging studies are necessary at this point. Conversely, lack of free air on plain x-ray does not rule out anastomotic leak.*
- *Delaying intervention for abdominal sepsis can lead to a catastrophic result, including sepsis and prolonged ICU stay, prolonged overall hospitalization, elevated hospital expenses, and often the patient's death.*

Recognizing Postoperative Intra-Abdominal Sepsis

Richard Davis, Winnie Mutunga

Richard Davis MD FACS FCS(ECSA)
AIC Kijabe Hospital
Kenya

Winnie Mutunga
AIC Kijabe Hospital
Kenya

October 2022

Resource-Rich Settings

CT scan of the neck, chest, or abdomen is extremely helpful for investigating postoperative patients. Oral contrast can be given and then the scan is timed according to the suspected area of leakage:

For esophagus, stomach or duodenum the images are taken within minutes of oral administration.

For small or proximal large bowel, the images are taken 30-60 minutes after oral administration.

For rectal or left sided colon, contrast is administered by enema.

If the patient's renal function is adequate, IV contrast can be administered as well, which helps diagnose abscesses and plan percutaneous drainage. IV contrast should be avoided in patients with sepsis.

Image-guided percutaneous drainage can avoid an operation for an abscess. Even in the case of anastomotic leakage, if the fluid collection is small, this is standard treatment in places where it is available. In such cases, postoperative nutrition is crucially important.

Endoscopic clip application has revolutionized the management of anastomotic leakage: a skilled endoscopist with the right equipment can often help the patient avoid an operation altogether. Any intra-abdominal fluid can then be managed by percutaneous drainage if necessary. In the cases discussed, this modality would have been effective on Case #1 and possibly on Case #2 if the diagnosis had been made

