

Rectal Biopsy for Hirschsprung's Disease

Catherine Jackson-Cole, Marlene Ishimwe, Jason Axt

Introduction:

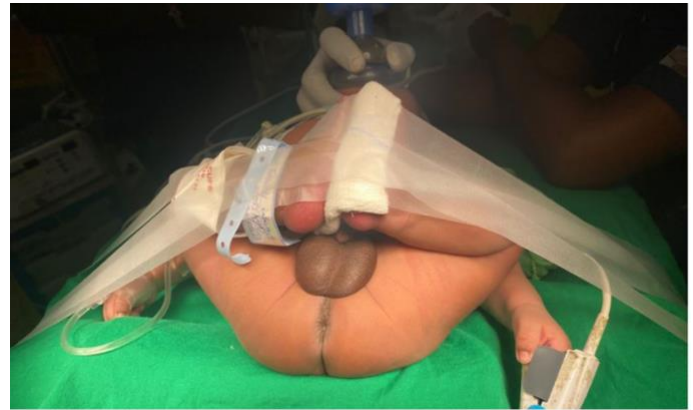Surgeons in resource-limited settings are often asked to evaluate children with chronic constipation for Hirschsprung's Disease. The triad of abdominal distention, vomiting, and passage of first meconium stool later than 24 hours raise suspicion of Hirschsprung's. Constipation can be caused by a multitude of dietary, environmental, and disease processes, and the clinician should maintain a broad differential. If the history is highly suggestive, or if the patient has remained refractory to medical treatment of constipation the patient should be evaluated for Hirschsprung's Disease.

A definitive diagnosis of is confirmed by pathological evaluation of full thickness rectal tissue taken at least 2 cm above the dentate line. This tissue will not have ganglion cells in the submucosal plexus. In addition, nerve hypertrophy can be demonstrated in the submucosal plexus and myenteric plexus. Adjuncts such as acetylcholinesterase and calretinin stains can also be used for greater diagnostic certainty, but the cost of specialized stains may be prohibitive.

Tissue can be obtained using a device for suction rectal biopsy, by endoscopic methods, or by an operative rectal biopsy. Often in resource-limited settings, the device for suction rectal biopsy is not available, and suction rectal biopsies may be of small size. In our experience, pathologists who evaluate for Hirschsprung's infrequently may not have a high degree of certainty. Therefore, it has been our practice to confirm presumptive diagnoses of Hirschsprung's with a full thickness rectal biopsy.

Steps:

1. The patient should not have active enterocolitis. If rectal washouts are being performed for presumed Hirschsprung's, a washout should be performed shortly before operating.
2. General anesthesia is induced, and the patient is placed in frog-leg lithotomy position at the end of the operating table.

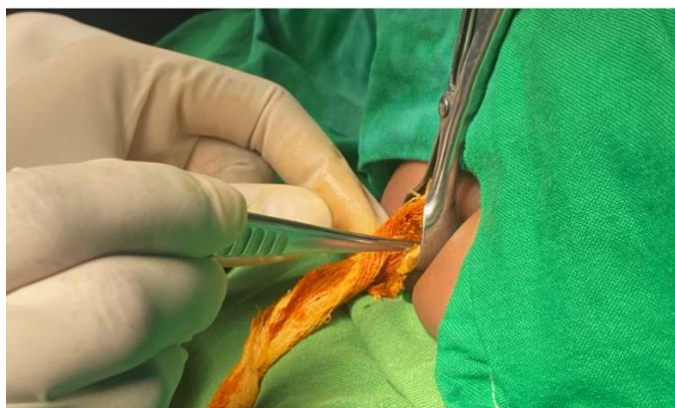


The proper position for rectal biopsy. Note that the child's buttocks are right next to the edge of the bed, so the bed itself does not block the surgeon's ability to view inside the anus from any angle necessary. Note also that due to the short duration of the procedure, general anesthesia is maintained with a mask held against the child's face by an expert anesthetist rather than through an endotracheal tube.

3. Prophylactic antibiotics are not necessary.
4. The operation may be done using sterile towels and sterile gloves with a protecting apron ("Mackintosh"). Full gowning and draping are not necessary.
5. The operating surgeon wears a surgical headlight.
6. A digital rectal exam is performed, and any abnormalities or strictures noted.
7. A lubricated nasal or anal speculum is introduced into the anus with the handle at the vertical position.
8. A suture is placed into a small betadine-soaked gauze covered with lubricating gel and it is placed into the rectum using a forceps. The suture is allowed to hang out of the anus and is directed above the speculum, so it is out of the way.

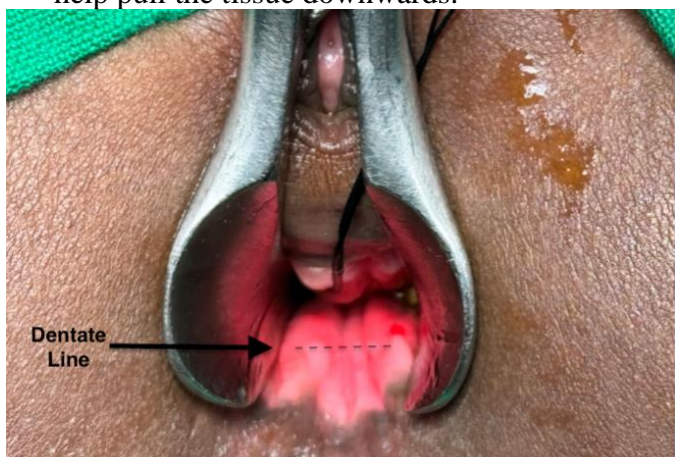Rectal Biopsy for Hirschsprung's Disease

Catherine Jackson-Cole, Marlene Ishimwe, Jason Axt



A nasal or small anal speculum is inserted with the handle facing upwards. A sutured betadine-soaked gauze is inserted through the anus into the rectum. The suture is directed upwards out of the way. It can be pulled to remove the gauze once the biopsy is complete.

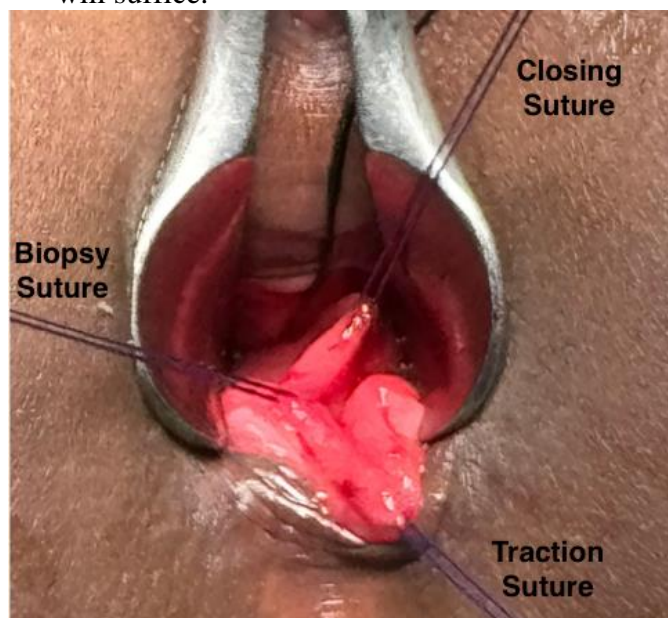
9. The dentate line is identified. Place a traction suture about 1cm above this structure. This will help pull the tissue downwards.



With insertion of the speculum, excellent positioning and relaxation under anesthesia, the dentate line as well as rectum proximal to it can easily be seen. Note also the suture attached to the gauze, out of the way behind the speculum.

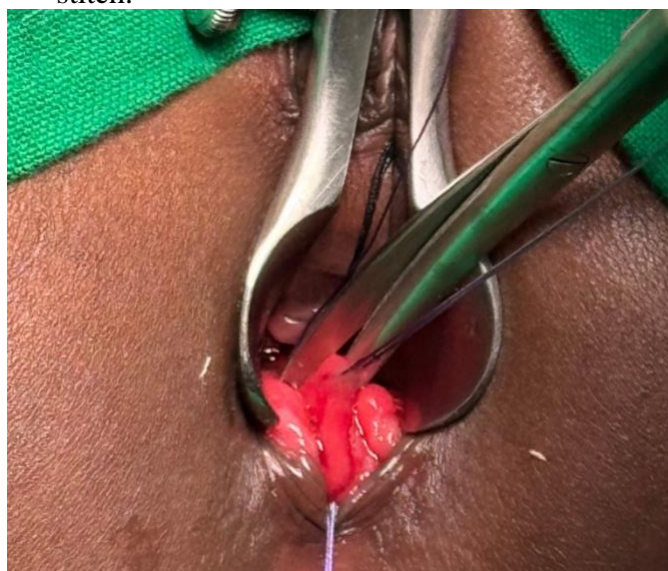
10. While holding tension on the traction suture, a second full thickness biopsy suture is placed 1 cm above it. Angle the needle 45 degrees forward and rotate the wrist. This will be the biopsy site. The suture is cut and held with a hemostat.
11. A third full thickness suture is placed 1 cm above the biopsy site and tied, without cutting off the needle. This will be used to close the biopsy site. A 3-0 polyglycolic acid (Vicryl)

suture is often used, but any absorbable suture will suffice.



All three sutures have been placed demonstrating their importance in elevating the tissue, underneath the Biopsy Suture, which will now be cut.

12. Holding all three sutures under tension a tissue scissors is used to make a vertical full thickness cut between the biopsy stitch and the closing stitch.

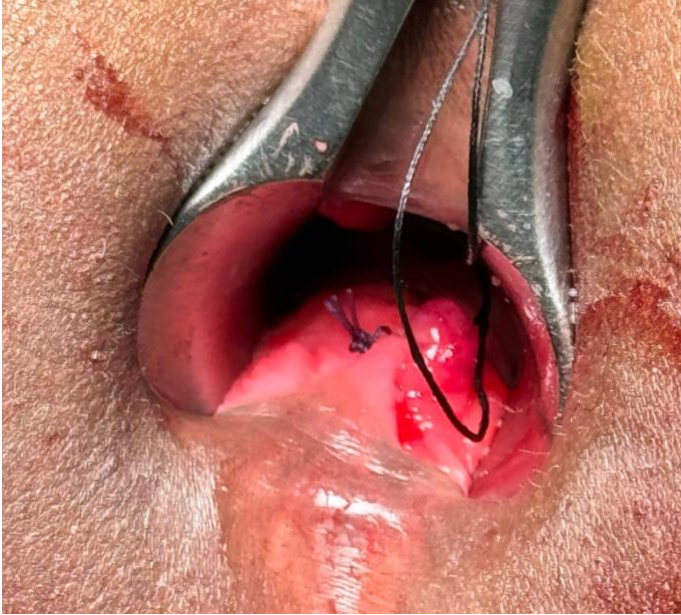

The first cut is made above the biopsy suture. The second will be made below it, yielding a full thickness piece of tissue about 2mm wide.

Rectal Biopsy for Hirschsprung's Disease

Catherine Jackson-Cole, Marlene Ishimwe, Jason Axt

13. Use the tissue scissors to cut tissue from beneath the biopsy stitch to connect the cuts and obtaining a ~2 mm piece of rectal tissue. The biopsy site will bleed briskly, but this will be controlled by closure.
14. Use the already placed closing suture to close both sides of the biopsy site in running locking fashion. Once the wound is closed, tie the suture to itself.



The completed closure, with the traction suture removed. The remaining suture is attached to the gauze.

- Preterm infants may not have fully developed nerves yet. Rectal biopsies should not be trusted until the infant has reached full term gestational age.

Catherine Jackson-Cole, MBChB
Marlene Ishimwe, MD
Jason Axt, MD MPH FAAP FCS(ECSA)
AIC Kijabe Hospital
Kenya

May 2024

15. Check for hemostasis, remove the speculum and the gauze.
16. All incisions and sutures placed should be above the dentate line and therefore painless. No postoperative analgesics are necessary.

Pitfalls

- Ensure that the biopsy is at minimum 1 cm above the dentate line, or the biopsy may be falsely read as no ganglion cells.
- Do not stricture the anus by being excessively “generous” with the closure- close only the mucosa adjacent to the wound.
- Avoid cutting the closure suture while taking the biopsy. It is difficult to replace that suture when there is bleeding, and one has lost the traction of the other suture.