

# Ureteroneocystostomy (Ureteral Reimplant)

George E. Koch, Niels V. Johnsen

## Introduction:

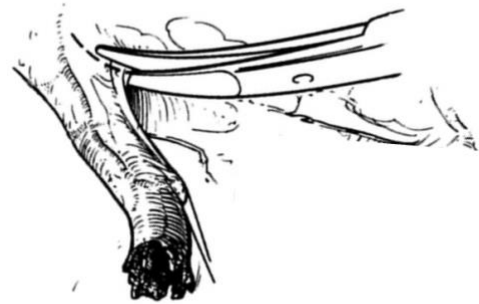
For distal ureteral injuries, healthy ureter proximal to the injury should be reimplanted directly into the bladder whenever possible. The bladder can be mobilized and secured close to the proximal ureter using the psoas hitch technique and reconstructed with a Boari flap as needed to bridge the gap to healthy ureter. A drain should be left at the site of the repair and a foley catheter placed for 1-2 weeks.

Ureteroneocystostomy proceeds in the following steps:

- Exploration, identification, and debridement of the injured distal ureter
- Mobilization of the bladder and direct anastomosis if appropriate
- Dissection of the psoas muscle and creation of a psoas hitch if appropriate
- Incision of the bladder and creation of a Boari flap as needed

## Steps:

1. If the site of the injury is apparent it should be exposed and evaluated. If the site of the injury is not apparent, the colon should be medialized along the White Line of Toldt to expose the retroperitoneum. The ureter can then be identified and exposed by beginning dissection at a known ureteral landmark, like the iliac bifurcation, and tracing it to the site of injury. Alternatively, for distal injuries, the bladder can be opened and the associated ureteral orifice cannulated with a wire or ureteral catheter or instilled with saline or methylene blue to help identify the injury. Be sure to open the bladder longitudinally and off midline so the incision can be incorporated into a Boari flap if needed (see below.)



*Mobilize the ureter without damaging its blood supply, which runs within the tissue around the ureter. Source: Burks FN, Santucci RA. Therapeutic Advances in Urology.*

<https://doi.org/10.1177/1756287214526767>

2. Once identified, the injured tissue should be inspected. Bruised or discolored tissue raises concern for devitalization and should be debrided.



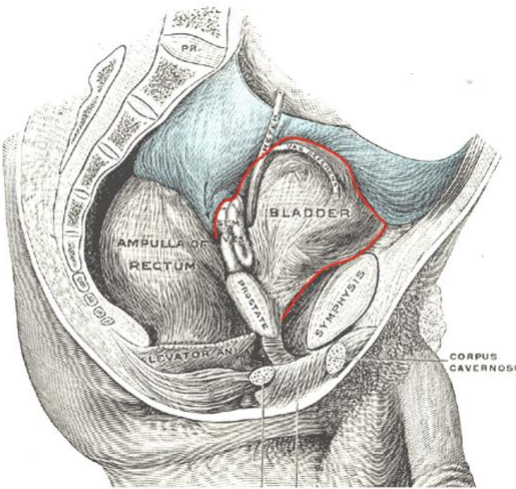
*Debride any devitalized or bruised ureter tissue. Source: Burks FN, Santucci RA. Therapeutic Advances in Urology.*

<https://doi.org/10.1177/1756287214526767>

3. The bladder is next mobilized by incising the bilateral medial umbilical ligaments and developing the Space of Retzius. The peritoneal wings on either side of the bladder can also be incised for further mobilization. The bladder can be filled and emptied via a foley catheter as needed to aid in mobilization.

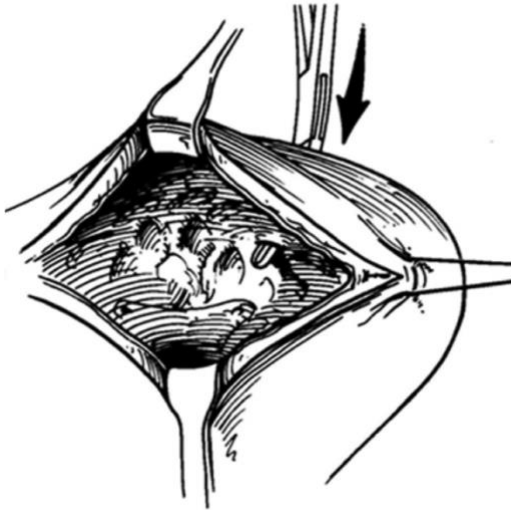
# Ureteroneocystostomy (Ureteral Reimplant)

George E. Koch, Niels V. Johnsen



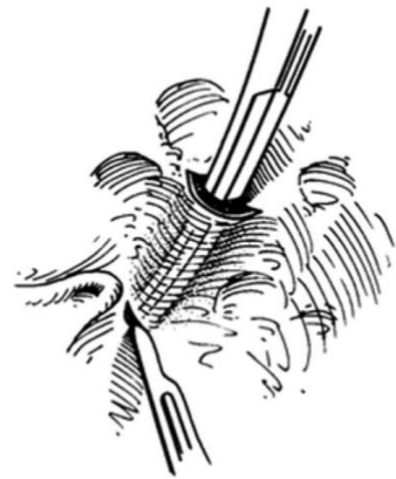
The bladder (shown here in a male) should be dissected off the surrounding peritoneal and retroperitoneal / retropelvic attachments, in the plane shown by the Red line. Take care not to damage the ureters or other surrounding structures. In the male, the seminal vesicles should remain attached to the bladder during dissection and the surgeon should be aware of the entry site of the vas deferens.

4. If the bladder and ureter reach each other without tension, the ureter can be reimplanted without further bladder reconstruction.



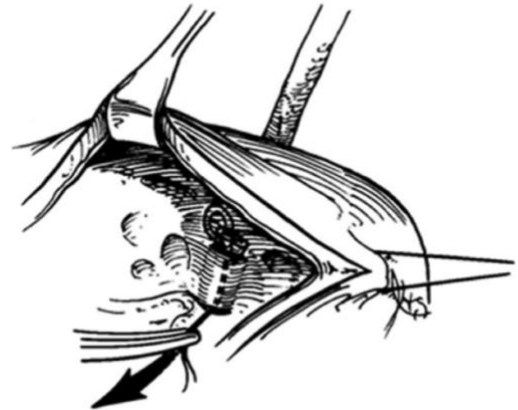
At the area where the ureter will enter the bladder wall, a hemostat is passed through all layers into the lumen of the bladder. Source: Burks FN, Santucci RA. Therapeutic Advances in Urology.

<https://doi.org/10.1177/1756287214526767>



A submucosal tunnel is made for about 1cm and a separate incision in the mucosa is made. Source: Burks FN, Santucci RA. Therapeutic Advances in Urology.

<https://doi.org/10.1177/1756287214526767>



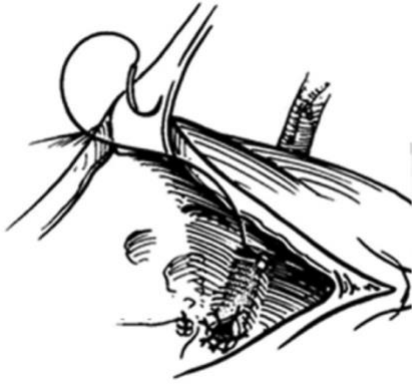
A suture is passed through the tip of the spatulated ureter and the ureter is passed through the tunnel with gentle traction on the suture. Source: Burks FN, Santucci RA. Therapeutic Advances in Urology.

<https://doi.org/10.1177/1756287214526767>

# Ureteroneocystostomy (Ureteral Reimplant)

George E. Koch, Niels V. Johnsen

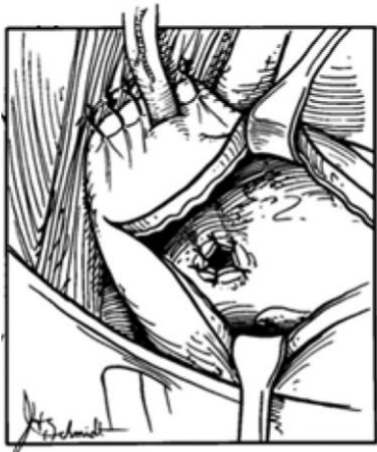
<https://doi.org/10.1177/1756287214526767>



*The mucosa of the spatulated ureter is anastomosed to the mucosa of the bladder with interrupted 4-0 or 5-0 absorbable suture. Source: Burks FN, Santucci RA. Therapeutic Advances in Urology.*

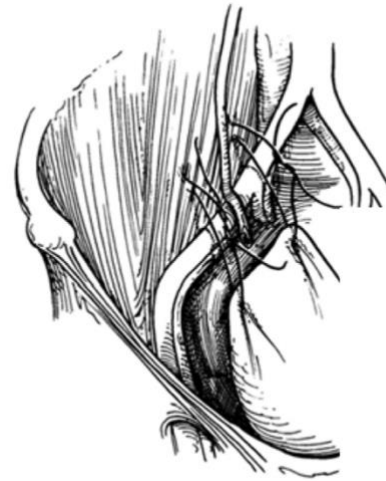<https://doi.org/10.1177/1756287214526767>

5. If the bladder reaches healthy ureter with some tension, it can be affixed to the psoas muscle to reduce tension on the anastomosis. The contralateral bladder pedicle can be further mobilized by ligating the superior vesical artery.
6. The psoas muscle is identified and exposed.
7. A longitudinal cystotomy is made off midline so a hand can then be placed in the bladder to push it up towards the psoas muscle to ensure a psoas hitch will effectively close the gap to healthy ureter. This can also be done with a handheld retractor.



*The longitudinal cystotomy, shown here after completed anastomosis, is made such that it could be converted into a Boari flap if needed, as described further below. Source: Burks FN, Santucci RA. Therapeutic Advances in Urology.*

8. The bladder is then pulled cranially and the posterior aspect is affixed to the psoas muscle and tendon using 2-0 absorbable suture, being careful to take longitudinal bites and avoid deep bites of the psoas, which endangers the femoral and genitofemoral nerves.



*Attachment of the mobilized bladder to the psoas muscle, taking care to avoid injury to the femoral and genitofemoral nerves: see the diagram under the "Pitfalls" section. Source: Burks FN, Santucci RA. Therapeutic Advances in Urology.*

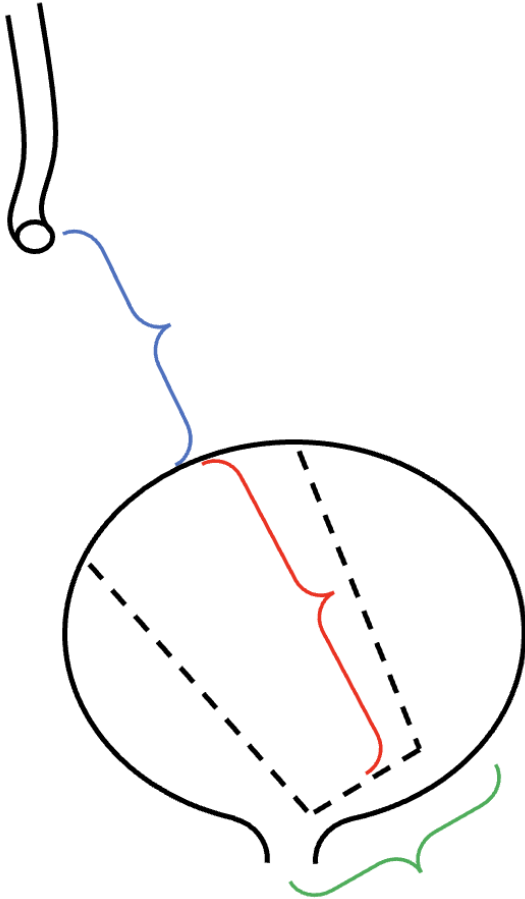
<https://doi.org/10.1177/1756287214526767>

9. If the bladder is still unable to reach healthy ureter without tension after this psoas hitch, a Boari flap can be performed.
10. A U-shaped flap is marked out on the anterior surface of the bladder with the pedicle at the cranial-most aspect of the bladder and the tip of the "U" towards the bladder neck. The length of the flap should be longer than the measured distance to healthy ureter as it will contract due to vasospasm and edema. The width should be at least half the length of the flap to ensure adequate blood supply.

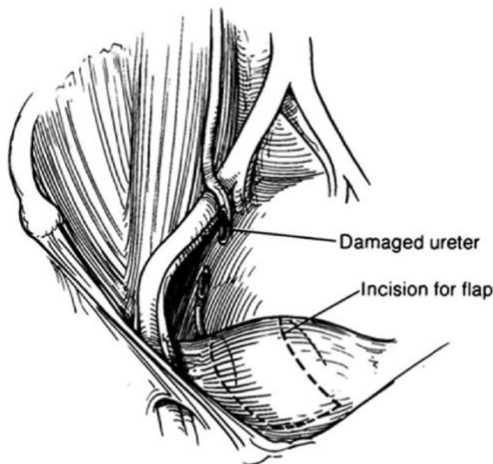
# Ureteroneocystostomy (Ureteral Reimplant)

George E. Koch, Niels V. Johnsen

<https://doi.org/10.1177/1756287214526767>

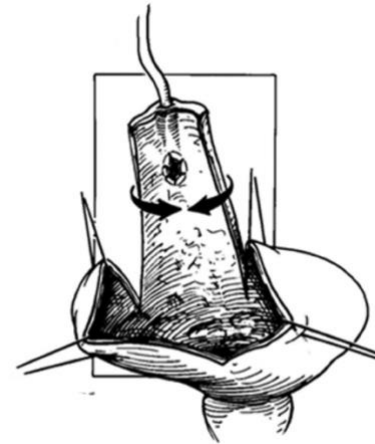


*Schematic of a Boari flap. The length of the flap (Red distance) should be 20% longer than the gap between the end of the ureter and the bladder (Blue distance.) The width of the flap (Green distance) should be at least  $\frac{1}{2}$  of its length and taper slightly towards the tip to avoid ischemia.*



*The planned Boari flap. Source: Burks FN, Santucci RA. Therapeutic Advances in Urology.*

11. The detrusor flap should be developed as a full thickness flap including serosa, muscle, and mucosa.
12. A full-thickness 1-2 cm hole is made in the posterior aspect of the Boari flap and the ureter is then reimplanted by pulling it through the hole. If the ureter does not reach the posterior aspect of the flap, it can be reimplanted into the proximal tip of the tabularized flap, however, the flap's blood supply may not be as robust in this location. Finally, some advocate for creating a short submucosal tunnel for reimplantation as shown in the figures.



*The Boari flap, shown after ureter implantation and before tubularization and closure. Source: Burks FN, Santucci RA. Therapeutic Advances in Urology.*

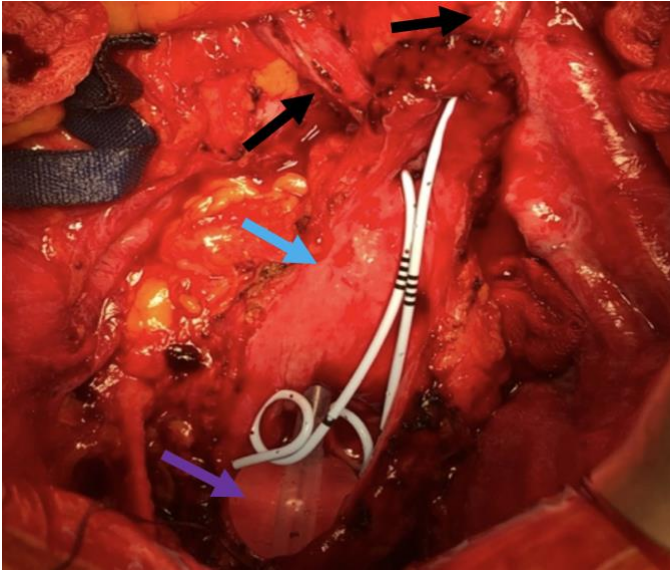
<https://doi.org/10.1177/1756287214526767>

13. The ureter should be spatulated to match the 1-2 cm cystotomy and then a circumferential mucosa-to-mucosa anastomosis should be done with interrupted 4-0 or 5-0 absorbable suture. A ureteral stent should be placed before closing the bladder.



# Ureteroneocystostomy (Ureteral Reimplant)

George E. Koch, Niels V. Johnsen



The open Boari flap after completed anastomosis, in this case to both ureters (Black arrows.) Stents are visible within the flap. The most cranial extent of the bladder, the base of the flap, is shown by the Blue arrow. The balloon of a urethral catheter inside the bladder is shown by the Purple arrow.

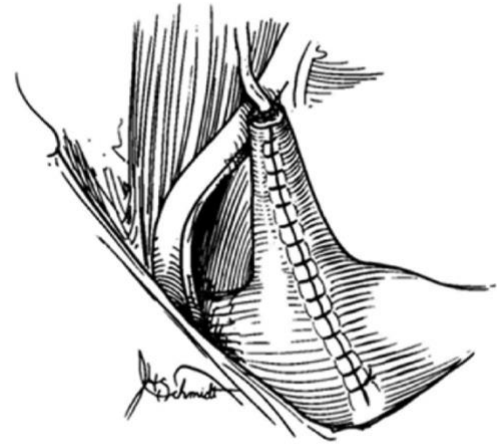
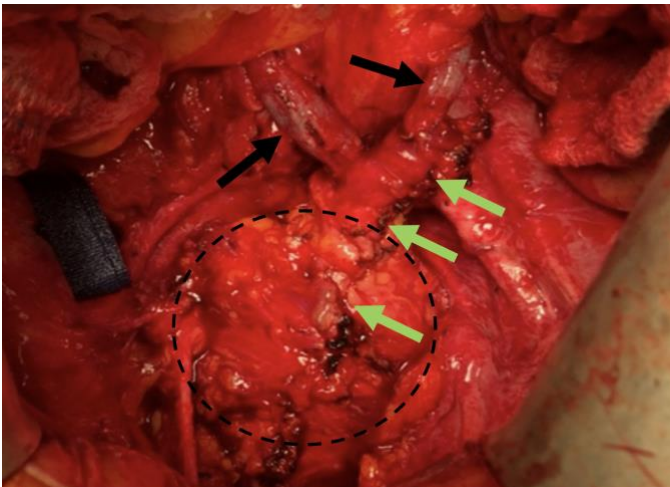


Illustration of the closed Boari flap. Source: Burks FN, Santucci RA. *Therapeutic Advances in Urology*.

<https://doi.org/10.1177/1756287214526767>

14. The bladder is then closed and the Boari flap tubularized by closing the bladder in 2 layers using 3-0 absorbable suture for the mucosa and 2-0 absorbable suture for the detrusor muscle and serosa.



The completed Boari flap, after closure and tubularization of the bladder and flap in two layers. The suture line is shown by the Green arrows. The two ureters are shown by the Black arrows. The outline of the bladder is shown by the Black dotted line.

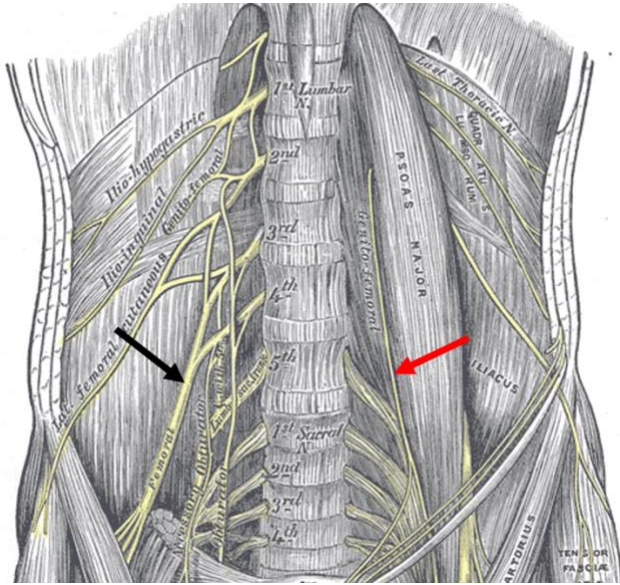
15. The peritoneum should be mobilized when possible and secured over the suture lines.
16. A drain should be left at the site of the repair and a foley catheter placed.
17. A leak test is performed with at least 150cc of saline instilled into the bladder via the foley catheter before closing the abdomen.
18. The stent is removed after 6 weeks with flexible or rigid cystoscopy. In settings without cystoscopy, some surgeons will use a foley catheter to pass the stent's string out the urethra prior to closing the bladder. This allows the stent to be removed later by simply pulling on the string. However, patients sometimes have difficulty managing a string coming from the urethra. This is especially true for children or people with diminished mental capacity. It is not infrequent in such occasions for the string to be pulled causing premature removal of the stent.

## Pitfalls:

- The femoral and genitofemoral nerves are both at risk of injury when performing a psoas hitch. The femoral nerve runs posterolateral to the muscle and the genitofemoral nerve runs anteromedial. Suturing the bladder to the psoas muscle using transverse or deep suture throws risks injury to these nerves and resultant postoperative numbness, paresthesias, and nerve palsies.

# Ureteroneocystostomy (Ureteral Reimplant)

George E. Koch, Niels V. Johnsen



Care must be taken when doing a psoas hitch to avoid damage to the femoral nerve posterolaterally (Black arrow) or the genitofemoral nerve anteromedially (Red arrow) on the psoas muscle.

- Mobilizing a short or narrow Boari flap risks inadequate length of the tubularized flap due to tissue contracture. Avoid this by measuring the distance from healthy ureter to bladder and then taking a flap that is at least 20% longer, with a pedicle at least half the length of the flap.

George E. Koch MD  
Vanderbilt University Medical Center  
USA

Niels V. Johnsen MD, MPH  
Vanderbilt University Medical Center  
USA